

## Evaluation of gallium maltolate as a treatment in brain tumor xenograft model

Kimberly Pechman<sup>1,2</sup>, Andrew Lozen<sup>1</sup>, Mona Al-Gizawiy<sup>2,3</sup>, Christopher R Chitambar<sup>4</sup>, Kathleen M Schmainda<sup>2,5</sup>, and Andrew Nencka<sup>6</sup>

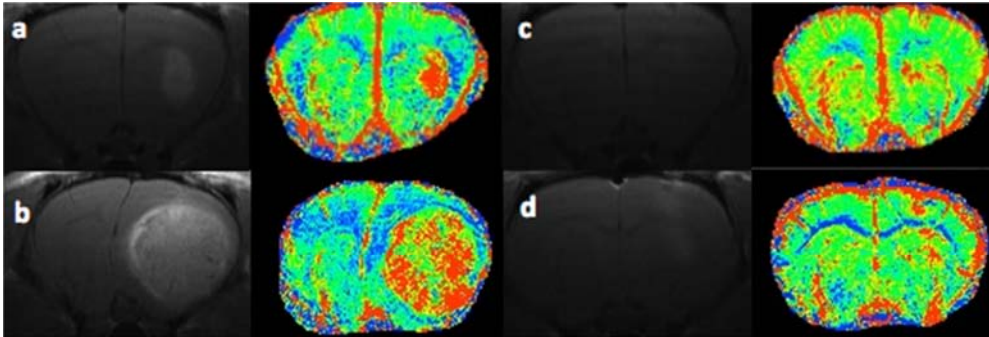
<sup>1</sup>Neurosurgery, Medical College of Wisconsin, Milwaukee, Wisconsin, United States, <sup>2</sup>Translational Brain Tumor Program, Medical College of Wisconsin, Milwaukee, Wisconsin, United States, <sup>3</sup>Radiology, Medical College of Wisconsin, Milwaukee, Wisconsin, United States, <sup>4</sup>Medicine, Medical College of Wisconsin, Milwaukee, Wisconsin, United States, <sup>5</sup>Radiology and Biophysics, Medical College of Wisconsin, Milwaukee, Wisconsin, United States, <sup>6</sup>Biophysics, Medical College of Wisconsin, Milwaukee, Wisconsin, United States

**Target Audience:** neuro-oncologists, neuro-radiologists, neuro-surgeons, brain tumor imaging scientists

**Purpose:** There are limited treatment options for glioblastomas, the most common and most aggressive primary brain tumor. Tumor cells have a high requirement for iron; the latter is taken up by cells through transferrin receptor-mediated endocytosis of transferrin-iron. These receptors are highly expressed on glioblastoma cells, which makes them an attractive target for transferrin receptor-directed therapies. Gallium is a group IIIa metal that can function as an iron mimetic in that it binds avidly to transferrin and is incorporated into cells through the transferrin receptor. No studies have been performed to determine the efficacy of gallium-based therapies in brain tumors. Consequently, the goal of this study was to evaluate gallium maltolate in the treatment of a U87 xenograft brain tumor model by evaluating changes in tumor blood volume and enhancing tumor volume.

**Methods:** *Animal Model:* U87 human grade IV astrocytoma cells were cultured, harvested, and 200,000 cells were injected into athymic rats using intracranial, stereotaxic approach. Gallium maltolate (50 mg/kg/day, n=5) or saline (n=3) was given i.v. via an alzet mini pump in the jugular vein. Imaging was performed on days 8 and 18. *MRI:* Images were obtained on a Bruker 9.4 T scanner fitted with a linear transmit coil, and surface receive coil. Both GE (TR=1.5s, TE=4,10,16,22,28ms, matrix=256) and SE (TR=3s, TEs=15,30,45,60,75, matrix=96) were collected before and after injection of MION (5 mg/kg). Subsequently, a spin-echo T1-weighted RARE sequence (TE/TR = 12.6ms/1500ms, FOV =3.5cm, matrix =256) was used to obtain T1 weighted images after the injection of 0.1mmol/kg Gd contrast agent.

**Figure 1**

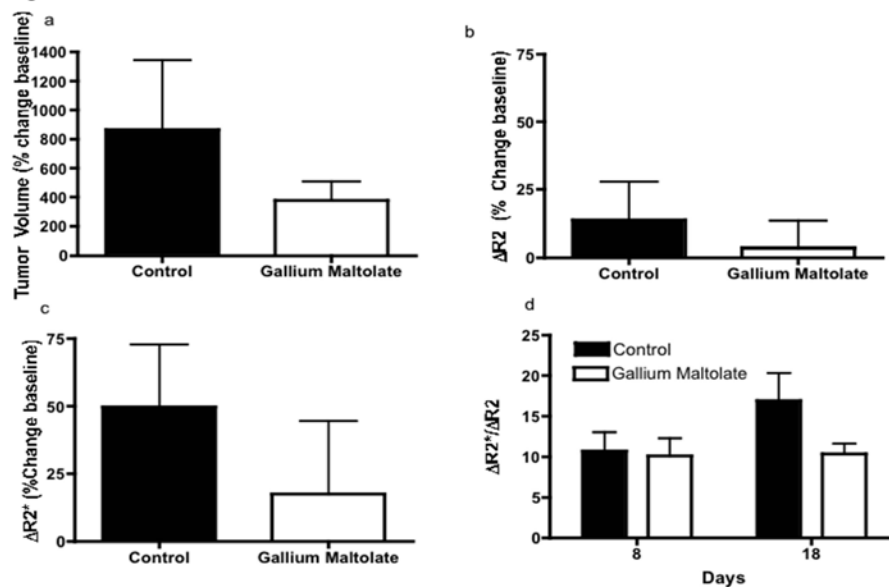


**Analysis:** Enhancing tumor volumes (reported in mm<sup>3</sup>) were determined from the post-contrast T1w images, in all slices showing enhancing tumor. The SE and GE data as a function of TE were fit to a mono-exponential curve for determination of T2 and T2\*. The SE and GE relaxation rate changes were then determined giving estimates of microvascular and total blood volume.  

$$((CBV_{\text{micro}} \approx \Delta R2 = R2_{\text{MION}} - R2_{\text{pre-MION}})$$

$$CBV_{\text{Total}} \approx \Delta R2^* = R2^*_{\text{MION}} - R2^*_{\text{pre-MION}})$$

**Figure 2**



**Results:** Figure 1 shows the post Gd-DTPA and  $\Delta R2^*$  ( $CBV_{\text{Total}}$ ) maps for a control (a: day 8 and b: day 18) and a treated rat (c: day 8 and d: day 18) at each imaging time point. Gallium maltolate (Fig 2a) inhibited tumor growth, as measured by enhancing tumor volume, compared to saline controls. Treatment shows decrease of  $CBV_{\text{micro}}$  and  $CBV_{\text{Total}}$  (Fig 2b, c) compared to the controls. The ratio of  $\Delta R2^*/\Delta R2$ , which is a measure of mean vessel diameter, increased in saline treated (Fig 2d) controls but remained unchanged for the gallium maltolate treated rats.

**Discussion:** To our knowledge this is the first study performed that uses physiologic MRI measurements to investigate the effects of gallium maltolate on brain tumor xenografts. Gallium inhibited tumor growth and blood volume in this model. The mean tumor microvessel diameter did not increase over the 10 day time period in gallium maltolate treated rats. However, the differences shown are not statistically

significant a result likely due to the small sample sizes, which is being remedied by ongoing additional studies. For the imaging studies included here tissue markers of proliferation (Ki67), hypoxia (HIF1 $\alpha$ ) transferring receptors, and vascular density (vWF) are being analyzed to provide additional information regarding mechanism of action. **Conclusion:** In general these results demonstrate, for the first time, that the novel gallium maltolate treatment holds promise for the treatment of malignant brain tumors. **Acknowledgements:** NIH/NCI RO1 CA082500, Advancing Healthier Wisconsin / MCW Translational Brain Tumor Program